

Correction of Penile Curvature by Rotation of the Corpora Cavernosa: A Case Report

Osama Shaeer, MD

Department of Andrology, Faculty of Medicine, Cairo University, and Kamal Shaeer Hospital—Andrology and ART, Cairo, Egypt

DOI: 10.1111/j.1743-6109.2006.00203.x

ABSTRACT

Aim. We report on the corporal rotation technique, customized for the management of ventral curvature in patients without hypospadias.

Methods. A male patient with ventral curvature of 90 degrees was operated on. The neurovascular bundle was mobilized for a short distance at the point of maximum curvature. The corpora cavernosa were approximated to each other in the dorsal midline by suturing pairs of longitudinal parallel incisions. To avoid urethral narrowing, minimal dissection was used to develop the groove on either side of the corpus spongiosum, to release it from its attachment to the rotated corpora cavernosa.

Results. Full correction of the curvature was achieved, without shortening, erectile dysfunction, or micturition problems.

Conclusion. Corporal rotation can be applied for the correction of ventral penile curvature in patients with and without hypospadias, without sacrificing penile length. **Shaeer O. Correction of penile curvature by rotation of the corpora cavernosa: A case report. J Sex Med 2006;3:932–937.**

Key Words. Peyronie's Disease of Tunica Albuginea; Shortening; Corporal Rotation; Penile Curvature

Introduction

A curved penis can have a substantially negative impact on a male, even in the mildest degree. A curved penis occurs in 4–10% of males unaccompanied by hypospadias [1,2], and in 0.08% along with hypospadias [3].

Penile curvature can be congenital or acquired. Congenital penile curvature may be due to a defective corpus spongiosum [4] or urethral plate [3], tethering skin, tethering Buck's fascia, or Dartos fascia [5], or due to a defective tunica albuginea of the corpus cavernosum on one side (corporal disproportion) [2]. Acquired penile curvature may be the result of Peyronie's disease, iatrogenic causes, trauma, or burns.

Surgical correction of penile curvature starts with release of the tethering tissues (chordee), after which the penis is reassessed. If curvature still persists, it is corrected by shortening the longer side of the tunica albuginea as in Nesbit [6] and modified Nesbit techniques [7], and tunica albuginea

plication [8]. Alternatively, correction can be achieved through elongating the shorter side by grafting [9]. Considering that Nesbit technique has resulted in a shorter penis in some cases [10], grafting the shorter side is a better option in severe cases. Unfortunately, grafting comes at a cost. Long-term follow-up data have showed that grafting can be complicated with graft contraction and erectile dysfunction [11].

Corporal rotation has been suggested as an alternative [12–15], where ventral curvature in hypospadias patients can be corrected by rotating the corpora cavernosa medially. This involved incising the ventral midline, and suturing the corpora to one another on the dorsal aspect either above the neurovascular bundle [13,14] or underneath it [15]. This ventral incision is only possible in hypospadias patients.

We report on the corporal rotation technique, customized for the management of ventral curvature of the penis, in patients without hypospadias.

Methods

A 22-year-old male patient with penile curvature was operated on. He reported ventral curvature that interfered with intromission, despite normal erectile function. International Index of Erectile Function (IIEF) questionnaire gave a score of 39, comprising high scores for questions about the quality of erection regardless intercourse, and low scores for questions involving intromission, reflecting the inability to penetrate the partner on account of the curvature (Table 1). Examination showed no fibrous plaques, no palpable chordee, and normal position of the urethral meatus. Artificial erection was induced by intracorporal Prostaglandin E1 and the curvature was examined. There was a ventral curve of 90 degrees (Figure 1), with the point of maximum curvature at the junction between the proximal one-third and the distal two-thirds of the penis. The degree of curvature was assessed by a protractor. Tape was used to measure the ventral and dorsal length in the erect state, with the proximal point at the bony pelvis and the distal point at the tip of the glans. The tape was also used to determine the circumference of the erect penis at the point of maximum curvature. Rigidity of the erect penis was normal. A concomitant duplex study confirmed normal erectile function.

Prior to surgery, the patient provided a written informed consent with special emphasis on the experimental nature of the procedure.

The procedure was performed under general anesthesia. The incision was subcoronal circumferential. The penis was de-gloved. Artificial erection was induced by saline infusion. The ventral side was inspected for tethering chordee. None was found except for a few bands of Buck's fascia that were resected, resulting in mild correction of the degree of curvature. Curvature was reassessed and the point of maximum curvature was marked.

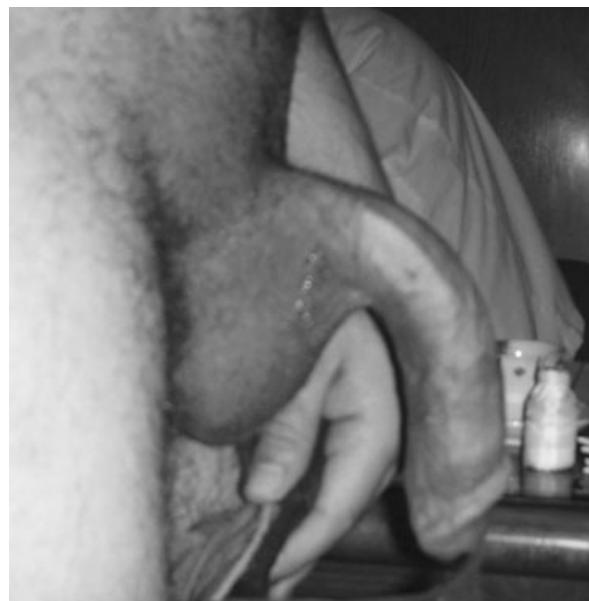

Figure 1 Preoperative erect penis showing a 90-degree ventral curve.

The urethra was calibrated with metal sounds to determine its average diameter so as to correct any urethral narrowing that may result from the procedure. Artificial erection was undone.

Using optical magnification, the neurovascular bundle was dissected off the corpora cavernosa for a short distance (3 cm) at the point of maximum curvature (Figure 2), minding the laterally coursing nerves. Elevation of the bundle exposed the dorsal aspect of the corpora cavernosa.

The tunica albuginea was incised for a length of 0.5 cm, short of the erectile tissue, on the dorsomedial aspect of both corpora cavernosa. The two parallel incisions were placed at the point of maximum curvature (Figure 3). The medial edges of the incisions were joined in the midline by slowly absorbable (Polydioxanone) inverted

Table 1 IIEF score before and after surgery

	IIEF score						Total score
	Degree of curvature	Erectile function	Satisfaction with intercourse	Orgasmic function	Desire	Overall satisfaction	
Before	90	21	3	10	3	2	39
	Answers to the questions concerning erectile function						
	1. How often were you able to get an erection during sexual activity? 5						
	2. How often were your erections hard enough for penetration? 5						
	3. How often were you able to penetrate your partner? 2						
	4. How often were you able to maintain your erection after you had penetrated your partner? 2						
	5. How difficult was it to maintain your erection to completion of intercourse? 3						
	15. How do you rate your confidence that you can get and keep your erection? 4						
After	0	30	12	10	10	6	68

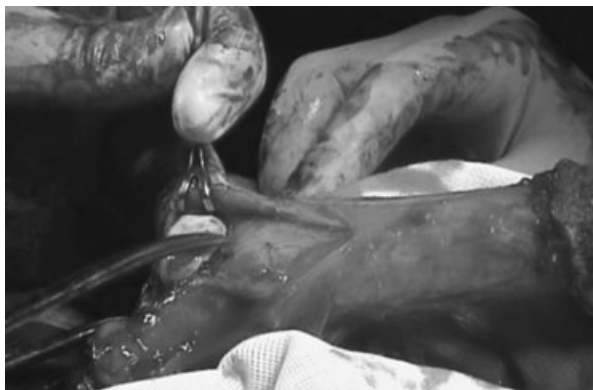

Figure 2 Artificial erection showing a 90-degree ventral curve, and elevation of the neurovascular bundle.

sutures. The lateral edges of the incisions were also approximated by sutures over the sealed medial edges (Figure 4). This resulted in dorsomedial rotation of the corpora (Figures 5 and 6). Artificial erection was reinduced. Penile curvature and caliber of the urethra were assessed. The caliber of the urethra was not compromised. The penis was almost straightened but not totally straight. It was decided that more rotation was needed. Further rotation was accomplished by the same aforementioned steps: suturing parallel incisions together, immediately distal to the preceding incisions. Both curvature and urethral caliber were re-evaluated. Eventually, the penis was fully straight and the caliber of urethra in the erect state was as measured prior to surgery. The dorsal incisions were 1.5 cm long.

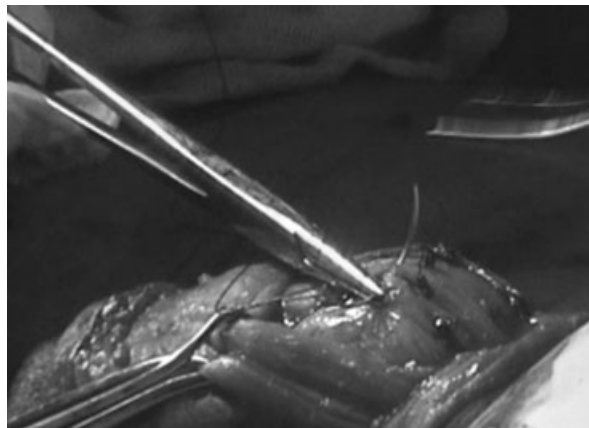


Figure 4 Suturing the corporal incisions together. The neurovascular bundle mobilized to the left side.

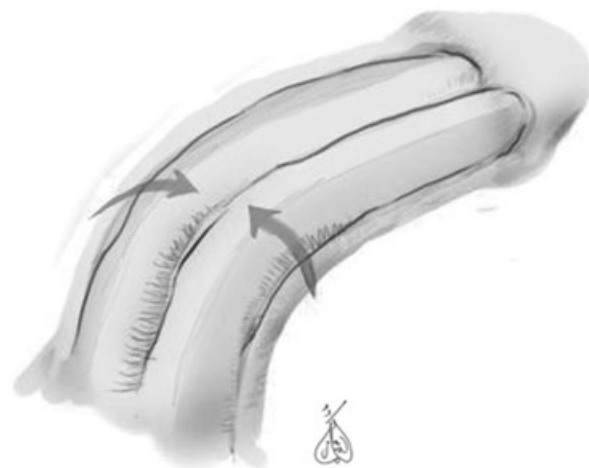

Figure 5 Direction of rotation of the corpora cavernosa.

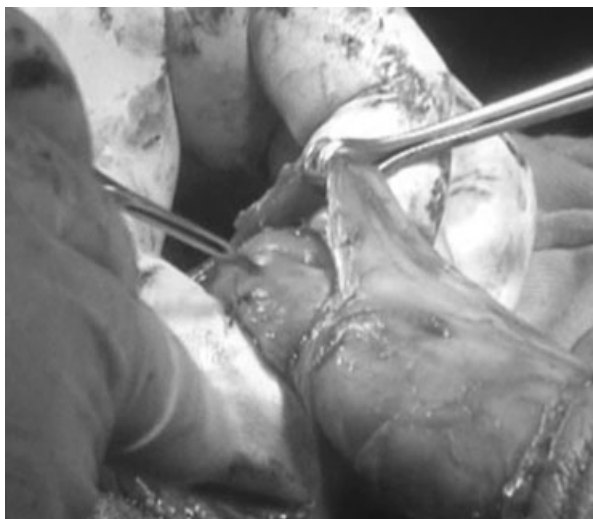

Figure 3 Incising the corpora cavernosa underneath the neurovascular bundle.

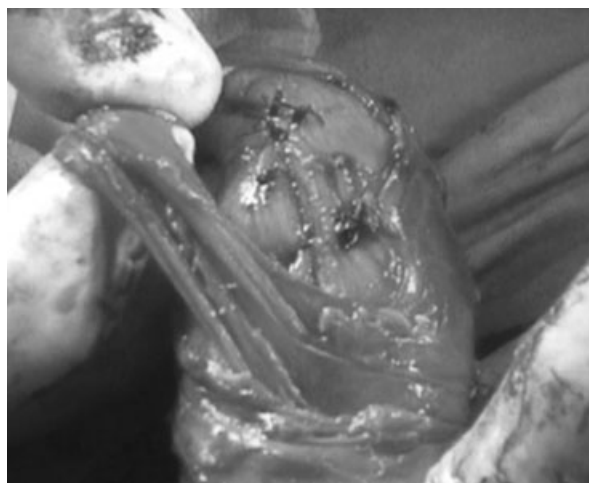


Figure 6 The corpora cavernosa approximated underneath the neurovascular bundle.

Under optical magnification, blunt-tip scissors were used to develop the gap on either side of the corpus spongiosum. This is the gap that separates the corpus spongiosum from the corpora cavernosa. This was performed to release the corpus spongiosum from the strands that join it to the rotated corpora cavernosa. This was a precautionary measure to prevent any future narrowing of the urethra that may result from the procedure. The skin incision was closed and the patient was discharged in the same day.

The patient was followed up for 14 months. By the end of the follow-up period, evaluations of penile curvature, penile length, circumference, and erectile function were carried out by artificial erection, concomitant duplex examination, and IIEF questionnaire.

Results

The curvature was fully corrected. The penis was straight (Figure 7). The postoperative dorsal length was 1 cm longer than the preoperative state. The postoperative ventral length was 3 cm

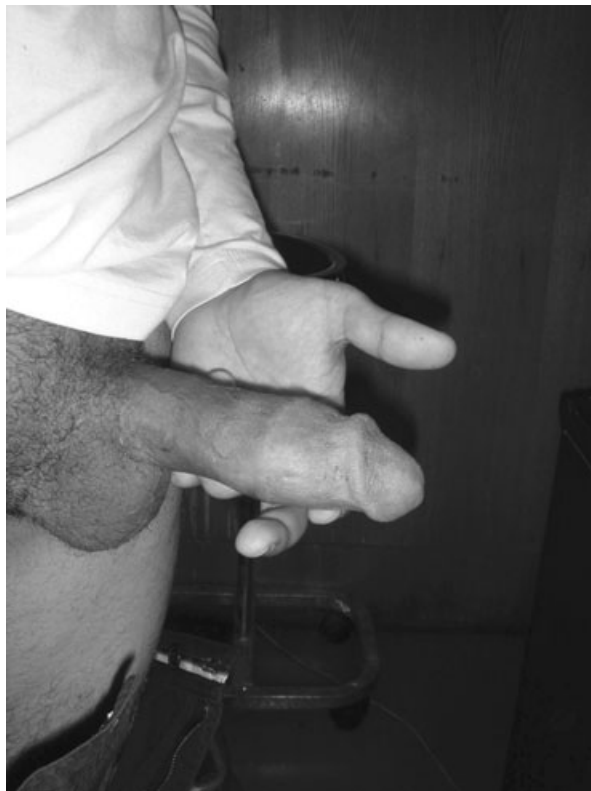

Figure 7 Postoperative appearance in the erect state (lateral view).



Figure 8 End result: full correction with increase in distal girth.

longer than the corresponding preoperative length.

Mild dimpling occurred dorsally at the point of the dorsal suture lines. The dimple was palpable in the erect state, but not visible. It was unnoticeable by the patient. The circumference at this point was no less than the preoperative girth. The distal shaft showed a 1.5 cm increase in circumference (12.5% of the original circumference) as a result of transposing the curvature to the lateral aspect of the penis (Figures 8 and 9). Subjectively, the patient was satisfied with the outcome and considered the gain in distal girth a plus.

Urination and ejaculation were both normal. Erectile function was normal as checked by penile duplex and by IIEF score, which improved from 39 to 68. Sensory perception at the glans was unchanged as reported by the patient.

Discussion

Corporal rotation for correction of penile curvature achieves full correction without sacrificing length [12–15], contrary to the principle of “shortening the longer side” applied in dorsal plication and Nesbit techniques [6,7] that results in a shorter penis [10]. Shortening would be a problem in case of severe curvature where the necessary plication will clearly reflect on the length of the penis. With our technique, it was possible to correct a 90-degree curve without shortening. On the contrary, there was an increase in length.

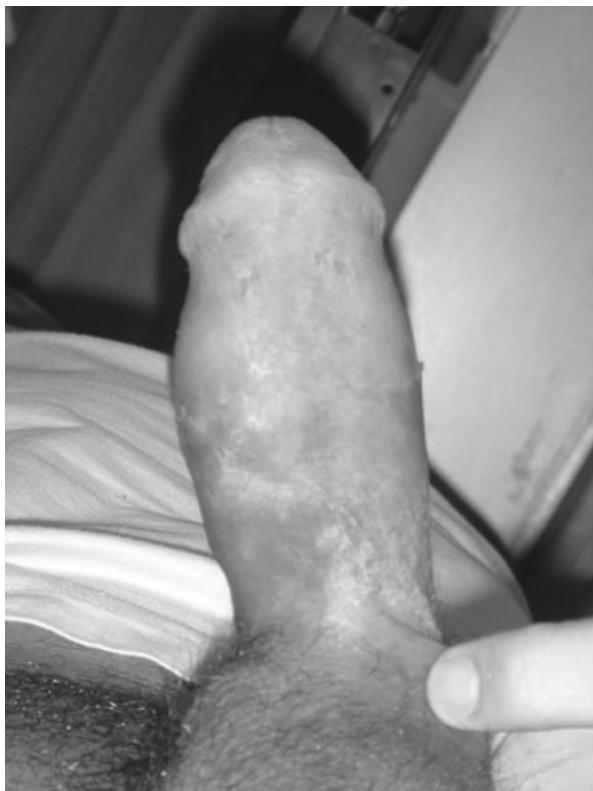

Figure 9 Postoperative appearance in the erect state (ventral view).

To understand how the dorsal length increased, it should be considered that upon erection, the increasing rigidity pushes the expanding corpora cavernosa away from the bony pelvis, forward. This forward expansion is limited mainly by the inherent elasticity of the tunica albuginea, except on the dorsal aspect, where attachment to the suspensory ligament limits forward expansion further. Rotation of the corpora brings the less hindered lateral aspects dorsally, resulting in a mild increase in dorsal length. This, combined with the ventral release of chordee, explains the gain in dorsal length. As for the ventral length gain, it is attributed to ventral release of tethering bands, and correction of the ventral curve.

Elongation of the shorter side of the corpora cavernosa can correct curvature without shortening, unless it is complicated by graft contraction [11]. Furthermore, erectile dysfunction is another reported complication [16]. Corporal rotation carries neither reported evidence nor theoretical potential for compromising erection, as compared with grafting techniques [12–15]. Corporal rotation does not involve the erectile tissue, the incisions stopping short of it. The erectile function of

our patient was preserved and his IIEF score improved, although this needs confirmation from future experience with more patients.

Corporal rotation has only been applied in hypospadias patients, where it involved a ventral incision separating the two corpora cavernosa [13–15]. This was thought to be necessary for achieving adequate rotation. In our experience, corporal rotation did not compromise the urethra. If it ever does, this can be detected intraoperative and corrected by releasing the corpus spongiosum from attachment to the corpora cavernosa as described, replacing the “ventral incision” that limited the application of the technique to hypospadias patients [13–15]. This is the main difference between our procedure and the previous procedures: it can be performed in patients without hypospadias, without splitting the corpora ventrally.

Injuring the neurovascular bundle has been the concern that has led to the modification of the technique proposed by Snow [13] and Kass [14] into that described by Decter [15] where the bundle is mobilized and the approximating sutures are applied underneath [15] rather than over it [13,14]. In this way, the bundle will not be strangulated by the sutures. However, Decter [15] mobilized the neurovascular bundle from the glans to an appropriate point on the dorsum proximally. We believe it may be better to mobilize the bundle right at the point of maximum curvature as guided by artificial erection, and for the shortest possible distance.

The alternatives to corporal rotation for correction of penile curvature without shortening include penile disassembly technique. Penile disassembly [17] involves extensive dissection and carries the risk of injury to the components of the penis during the process, contrary to the relatively minor dissection in case of corporal rotation.

A drawback of our technique may be the change in penile girth, with the distal increase in circumference. However, considering that the change in girth was 12.5% after correction of a curvature of 90 degrees without any loss in length, it may be possible that in milder degrees of curvature, the change in girth will be negligible, as the change in girth is proportional to the degree of rotation necessary for correction, which in turn is proportional to the degree of curvature. Furthermore, this change in shape—if undesirable—should be weighed against the degree of shortening, erectile dysfunction, and other complications prone to occur in the process of correction of extreme degrees of curvature with other techniques.

Another drawback is the possibility of injuring the neurovascular bundle during mobilization. This has not happened in the case at hand, and is avoidable by using optical magnification and meticulous dissection.

Conclusion

Corporal rotation can be applied for the correction of ventral penile curvature in patients with and without hypospadias, without sacrificing penile length.

Corresponding Author: Osama Kamal Zaki Shaeer, MD, 21 Gaber Ibn Hayan St., Dokki, Cairo, Egypt 12311. Tel: (+20) 202-335-9047; Fax: (+20) 202-760-5181; E-mail: dr-osama@link.net

Conflict of Interest: None.

References

- 1 Culp OS, McRoberts JW. Hypospadias. In: Alken CE, Dix VW, Goodwin WE, editors. Encyclopedia of urology. New York: Springer-Verlag; 1968:11307-44.
- 2 Kramer S, Aydin G, Kelalis P. Chordee without hypospadias in children. J Urol 1982;128:559-61.
- 3 Baskin L, Duckett J, Lue T. Penile curvature. Urology 1996;48:347-56.
- 4 Devine C Jr, Horton C. Chordee without hypospadias. J Urol 1973;110:264-7.
- 5 Kaplan G, Brock W. The etiology of chordee. Urol Clin North Am 1981;8:383-7.
- 6 Nesbit RM. Congenital curvature of the phallus: Report of three cases with description of corrective operation. J Urol 1965;93:230.
- 7 Nesbit RM. Operation for correction of distal penile ventral curvature with and without hypospadias. Trans Am Assoc Genitourin Surg 1966;58:12-4.
- 8 Baskin LS, Duckett JW. Dorsal tunica albuginea plication for hypospadias curvature. J Urol 1994;151:1668-71.
- 9 Devine C Jr, Horton C. Use of dermal graft to correct chordee. J Urol 1975;113:56-8.
- 10 Daitch JA, Angermeier KW, Montague DK. Modified corporoplasty for penile curvature: Long-term results and patient satisfaction. J Urol 1999;162:2006-9.
- 11 Hafez AT, Smith CR, McLorie GA, El-Ghoneimi A, Herz DB, Bägli DJ, Khoury AE. Tunica vaginalis for correcting penile chordee in a rabbit model: Is there a difference in flap versus graft? J Urol 2001;166:1429-32.
- 12 Koff SA, Eakins M. The treatment of penile chordee using corporal rotation. J Urol 1984;131:931.
- 13 Snow BW. Transverse corporal plication for persistent chordee. Urology 1989;34:360.
- 14 Kass EJ. Dorsal corporal rotation: An alternative technique for the management of severe chordee. J Urol 1993;150:635.
- 15 Decter RM. Chordee correction by corporal rotation: The split and roll technique. J Urol 1999;162(3 Pt 2):1152-4.
- 16 Dalkin BL, Carter MF. Venogenic impotence following dermal graft repair for Peyronie's disease. J Urol 1991;146:849-51.
- 17 Perovic SV, Djordjevic ML, Djakovic NG. A new approach to the treatment of penile curvature. J Urol 1998;160(3 Pt 2):1123-7.