

THE JOURNAL OF
**Sexual
Medicine**

**TORSION OF THE PENIS IN ADULTS: PREVALENCE AND SURGICAL
CORRECTION**

Journal:	<i>Journal of Sexual Medicine</i>
Manuscript ID:	JSM-08-2007-295
Manuscript Type:	Original Research
Keywords:	torsion, penis, dartos, realignment, congenital
Subject Area:	Genital lengthening/girth enhancement surgery < SPECIAL PROBLEMS < MALE



review

TORSION OF THE PENIS IN ADULTS: PREVALENCE AND SURGICAL CORRECTION

Introduction

Torsion of the penis is a condition where the penis rotates around its longitudinal axis. This has been well documented in the literature as a congenital malformation¹. It may also occur as an iatrogenic complication to penile surgery such as hypospadias repair².

A unique case report described a rare incident of penile necrosis on top of torsion³. This patient had spina bifida, loss of sensation below T10, spinal malformations that prevented him from visualizing the penis, and was catheterized on the long term. After untwisting the penis, it attained a 90 degree clockwise rotation from the neutral position, which appeared to be the normal position, denoting a possible predisposition due to congenital torsion. The phallus was lost.

Congenital torsion frequently passes unnoticed, and rarely do patients present with torsion as a complaint, especially that it does not hinder sexual activity. Nevertheless, some patients are heavily pounded by the psychological burden of penile torsion, and request correction.

This work is a description of our experience with various ways of surgical correction of congenital torsion of the penis in adults. It is also a report on the prevalence of various degrees of congenital penile torsion among a special patient group with infertility or erectile dysfunction, as a pilot study for the actual prevalence of this abnormality among the general population.

Patients and Methods

Surgical correction:

Sixteen cases with congenital torsion of the penis ranging from 45 to 90 degrees who were operated upon (picture 1, picture 2). Those subjects complained exclusively of torsion, had normal sexual function as concluded from history taking as well as IIEF-5 (International Index of Erectile Function) scores and had no associated anatomical abnormalities. Average age was 24 years. The 16 patients were chosen from among a larger group of subjects with torsion of the penis. Exclusion criteria were milder degrees of torsion, associated erectile dysfunction or other anatomical abnormalities such as curvature of the penis. All subjects provided written informed consents as to the value, success potential and possible complications of the surgical procedure.

Torsion of the penis was recorded in both the flaccid and erect states prior to surgery. Duplex study was also performed to exclude erectile dysfunction.

The procedure started with induction of artificial erection by intracorporal injection of PGE1 (Prostaglandin E1). Torsion was noted in terms of degree and direction. Degloving

1
2
3 was performed through a subcoronal incision (Picture 3). In most cases, degloving had
4 minimal or no effect on torsion. Surgical correction was achieved by counter-rotation,
5 using a Dartos flap in 8 cases, and skin realignment in the other 8.
6
7

8 A Dartos flap was developed in 8 cases off of the dorsal or dorsolateral skin of the base
9 of the penis (Picture 4). The flap was widely based to assure vascularization, and was
10 thick enough to maintain its own integrity while not compromising skin vascularity
11 (Picture 5). The flap was rotated across the dorsum of the penis in the same direction of
12 the torsion (clockwise or anticlockwise). The tip of the flap was sutured distally to the
13 lateral aspect of the tunica albuginea with sturdy inverted sutures (Picture 6, Picture 7).
14 This counter-rotation corrected torsion (Picture 8). Readjustment of the position of the
15 flap's tip was performed according to the desired degree of counter-rotation. Further
16 adjustments could be made by plication or release of the proximal edge of the flap. The
17 degloved skin was sutured back to its original position.
18
19

20
21 As to the 8 cases of skin realignment, the edge of the degloved skin was rotated in the
22 same direction as that of penile torsion and sutured in this realigned position to the other
23 edge, thereby achieving counter-rotation (Picture 9). Sutures were placed on two levels:
24 Dartos and skin. Again, the alignment of edges was verified and revised according to the
25 degree of counter-rotation desired.
26
27

28 Artificial erection was undone and torsion was re-evaluated in the flaccid state. Minor
29 revision was required in one case. Priority was given to correction of torsion in the erect
30 position.
31
32

33 No urinary diversion was required. The procedure was conducted in an average of 30
34 minutes. Patients were discharged in the same day and were advised resume daily activity
35 the next day, and to postpone sexual activity for 3 weeks.
36
37

38 Epidemiologic study:

39
40 Through 3 years from 2003 to 2006, as part of the routine examination, we recorded the
41 presence or absence of torsion and its degree, as well as whether or not it was
42 bothersome, among an average of 4000 patients that consulted 2 specialized centers each
43 year for reasons of infertility or sexual dysfunction, a total of 12307 patients. Torsion was
44 inspected in the flaccid position, and was classified into mild (5-30 degrees), moderate
45 (30-60 degrees) and severe (more than 60 degrees). The degree of torsion in the erect
46 state was not inspected but was rather inquired about, and evaluated subjectively by the
47 patient and was classified in the same way according to the patient's own evaluation.
48 Simple questioning rather than specialized questionnaire was used to evaluate the impact
49 of torsion on psyche and sexuality. Patients presenting with other anatomical
50 abnormalities or with history of penile surgery or trauma were excluded.
51
52
53

54 Results

55
56 Surgical correction:
57
58
59
60

1
2
3
4
5 Full correction was achieved in all cases in the erect state, and in 80% of cases in the
6 flaccid state. Residual torsion in the flaccid state was of minimal degree. The
7 postoperative period was uneventful except for one patient who suffered partial wound
8 gaping that required secondary sutures. Sexual function was verified by IIEF-5 score and
9 was confirmed as normal. Unfortunately, none of the subjects accepted intracorporal
10 injection for confirming potency and photographic documentation.
11

12
13 Average operative time was around 10 minutes longer in the Dartos flap group. Surgery
14 was much faster and easier in the realignment group. In one case with 90 degree torsion
15 from among the Dartos flap group, mild dimpling occurred at the base of the flap in the
16 erect state. In another case with 90 degree torsion from among the realignment group, the
17 patient complained of what he described as annoying deviation of the frenular line
18 (median raphe).
19

20
21 Epidemiologic study:
22

23
24 After applying the exclusion criteria, the total number of subjects was 11,340.
25 Collectively, torsion was present in 11.993 % (n=1360). Direction of torsion was
26 clockwise in 35% of subjects and anticlockwise in 65%. Degree of torsion in the flaccid
27 state was mild in the majority of cases (80%), moderate in 15% and severe in 5%. Forty
28 five percent of cases subjectively confirmed that almost the same degree of curvature was
29 present in the erect state. The rest stated that the degree of torsion was less evident upon
30 erection. Only 2.2% of subjects (n=30) were bothered by the condition to the extent of
31 accepting a surgical solution. They were mostly among those with severe curvature. No
32 etiology or point of onset was identifiable in any of the cases studied, indicating a
33 probable congenital nature.
34
35

36 Discussion

37
38
39 Several reports have referred to isolated congenital penile torsion^{1,4}. The reported
40 methods for surgical correction included mere degloving of the penis¹, counter-rotation
41 by a Dartos flap², wedge resection and plication of the tunica albuginea⁴, suturing the
42 lateral edge of the corpus cavernosum to the pubic periosteum⁵, and skin incision-
43 realignment⁶.
44

45
46 All the above stated treatment measures were described in the pediatric age group. Our
47 work addresses penile torsion in adults. Artificial erection is crucial step to success of
48 repair, contrary to the trend in the previous reports. Rectification is performed in the erect
49 state and retouched in the flaccid state if necessary. In this scenario, we found skin
50 incision and realignment to be of comparable results to Dartos flap technique.
51 Considering that the latter involves development of a well-vascularized flap, still
52 preserving vascularity of the penile skin, it may be relatively more difficult on the
53 technical side. Most pediatric surgeons and pediatric urologists are familiar with
54 development of such flap, but in case such experience is not available, skin realignment
55 should be adequate for most cases, and is much easier and less time consuming.
56
57
58
59
60

We suspect that torsion of more than 90 degrees may require a combination of the two techniques. We cannot confirm this impression since the maximum degree we encountered was 90 degrees. We felt that excision and plication of the tunica albuginea may be unnecessary considering that extra-corporeal measures did suffice.

To our knowledge, no studies addressed the overall prevalence of congenital torsion of the penis among the general population or within specialized patient groups. Our study reports the prevalence of various degrees of torsion of the penis in a large group that is of a rather special nature: those seeking help in the field of Andrology. Nevertheless, it may reflect to some extent the prevalence among the general population. Torsion was detected in a considerable percentage of the study group (11.993 %), but was bothersome in a minority of subjects (2.2%), particularly among those with more severe torsion (5%). Neither the condition nor its repair had impact on sexual function as confirmed by IIEF-5 scores. This indicates that congenital torsion has cosmetic rather than functional impact. On the other hand, surgical repair was easy and successful to the extent that it may be justified merely for improving cosmetic status.

Conclusion

Torsion of the penis could be detected in 11.993 % patients consulting an Andrology clinic, a number that may reflect the prevalence among the general population. The condition is rarely troublesome. In the rare cases with extreme degrees and cosmetic complaints, surgical repair can easily be accomplished by degloving and skin realignment. Dartos flap technique may be utilized if the former is inadequate.

Legends

- Picture 1: Dartos flap case prior to correction.
- Picture 2: Skin realignment case prior to correction.
- Picture 3: Degloving and artificial erection.
- Picture 4: Dissection of the Dartos flap.
- Picture 5: Dartos flap developed.
- Picture 6: Suturing of the Dartos flap.
- Picture 7: Dartos flap in place.
- Picture 8: Dartos flap case after correction.
- Picture 9: Skin realignment case after correction.

References

- 1-Pomerantz P, Hanna M, Levitt S, Kogan S. Isolated torsion of penis. Report of 6 cases. *Urology* 1978, 11(1): 37-9.
- 2-Fisher PC, Park JM. Penile Torsion Repair Using Dorsal Dartos Flap Rotation. *J Urol* 2004, 171: 1903–1904.
- 3-Raza AS, Mcneill A, Halliday P. Penile Necrosis Secondary To Spontaneous Penile Torsion. *J Urol* 2001, 166: 215.

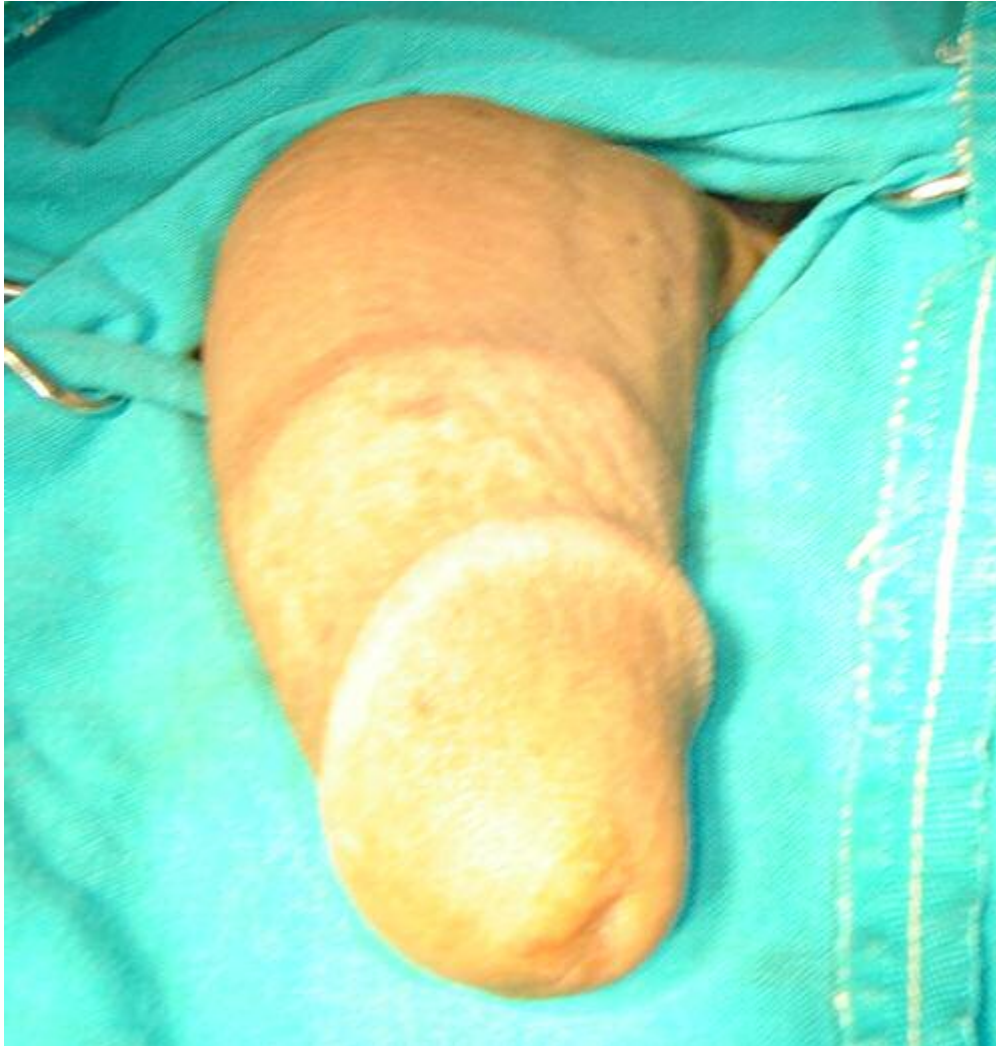1
2
3 4-Slawin KM, Nagler HM: Treatment of congenital penile curvature with penile torsion:
4 a new twist. J Urol, 147: 152,1992.

5 5-Zhou L, Mei H, Hwang AH, Xie HW, Hardy BE. Penile torsion repair by suturing
6 tunica albuginea to the pubic periosteum. J Pediatr Surg 2006, 41(1):e7-7-

7 6-Azmy A, Eckstein HB. Surgical correction of torsion of the penis. Br J Urol 1981, 53:
8 378.
9
10
11
12
13
14
15
16
17
18
19
20
21
22
23
24
25
26
27
28
29
30
31
32
33
34
35
36
37
38
39
40
41
42
43
44
45
46
47
48
49
50
51
52
53
54
55
56
57
58
59
60

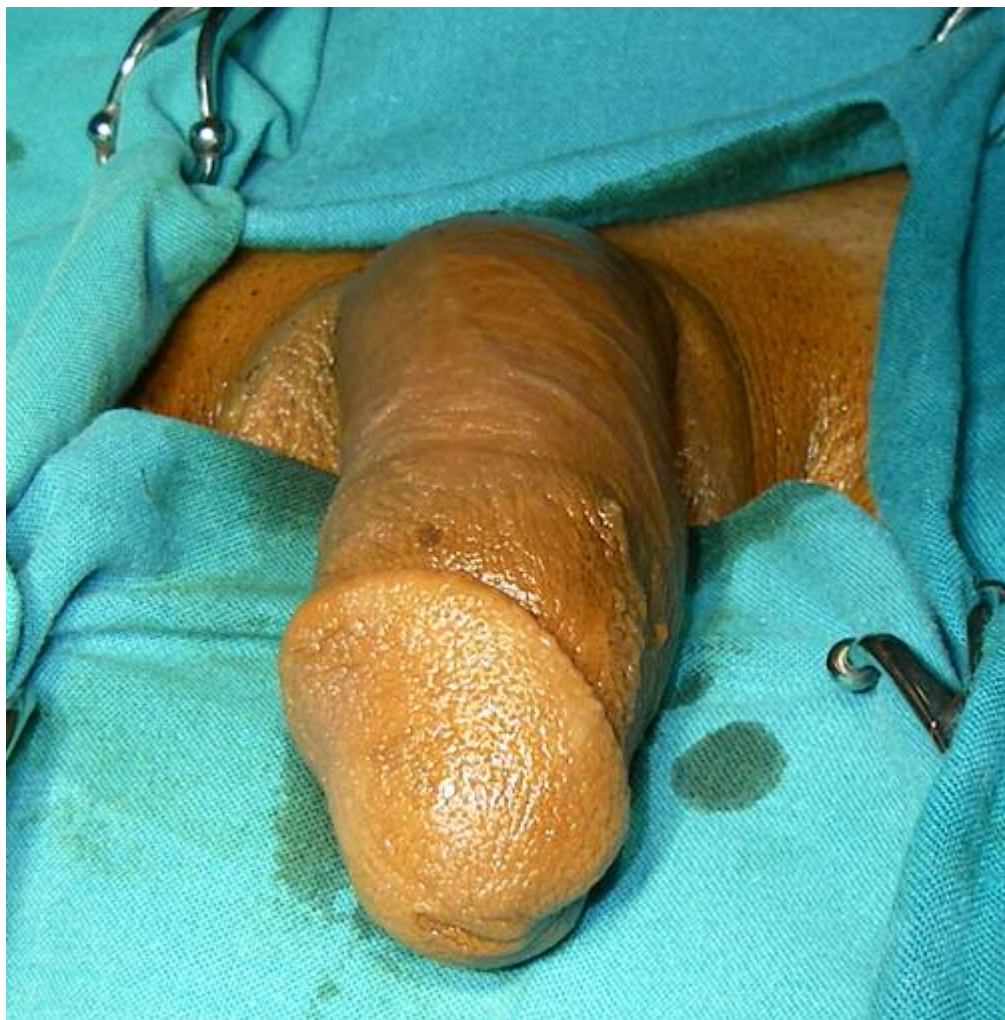For Peer Review

1
2
3
4
5
6
7
8
9
10
11
12
13
14
15
16
17
18
19
20
21
22
23
24
25
26
27
28
29
30
31
32
33
34
35
36
37
38
39
40
41
42
43
44
45
46
47
48
49
50
51
52
53
54
55
56
57
58
59
60



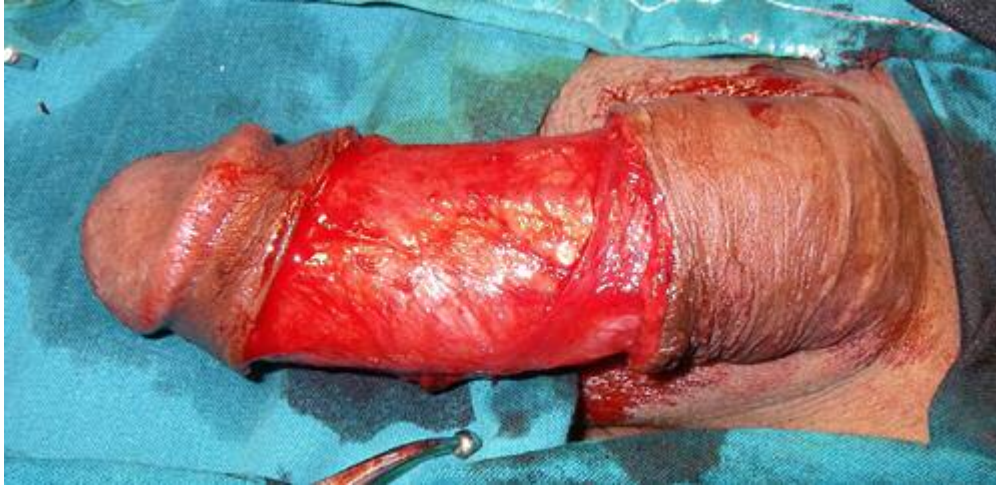Dartos flap case prior to correction.
176x184mm (72 x 72 DPI)

1
2
3
4
5
6
7
8
9
10
11
12
13
14
15
16
17
18
19
20
21
22
23
24
25
26
27
28
29
30
31
32
33
34
35
36
37
38
39
40
41
42
43
44
45
46
47
48
49
50
51
52
53
54
55
56
57
58
59
60



Skin realignment case prior to correction.
176x178mm (72 x 72 DPI)

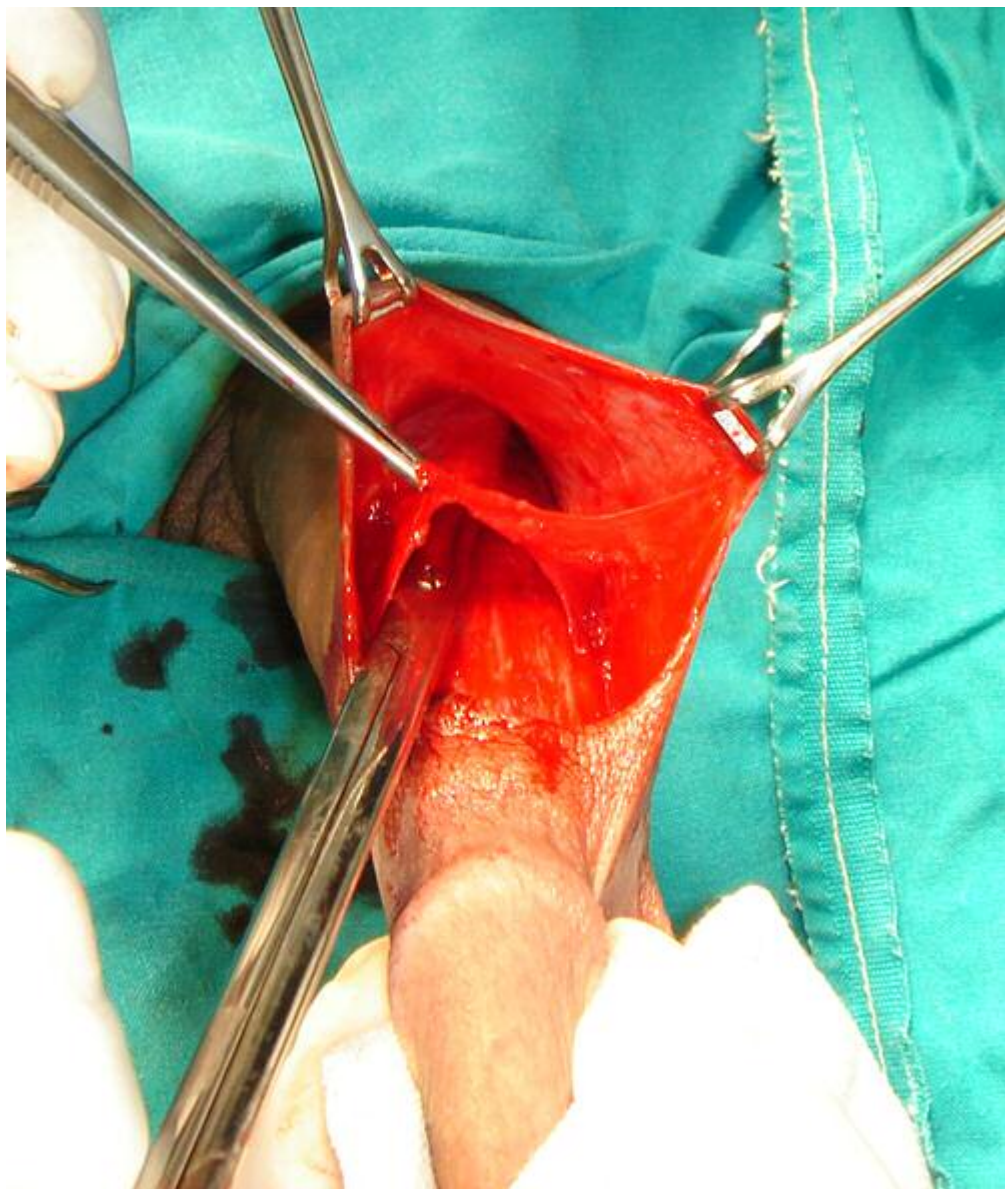
1
2
3
4
5
6
7
8
9
10
11
12
13
14
15
16
17
18
19
20
21
22
23
24
25
26
27
28
29
30
31
32
33
34
35
36
37
38
39
40
41
42
43
44
45
46
47
48
49
50
51
52
53
54
55
56
57
58
59
60



Degloving and artificial erection.
176x85mm (72 x 72 DPI)

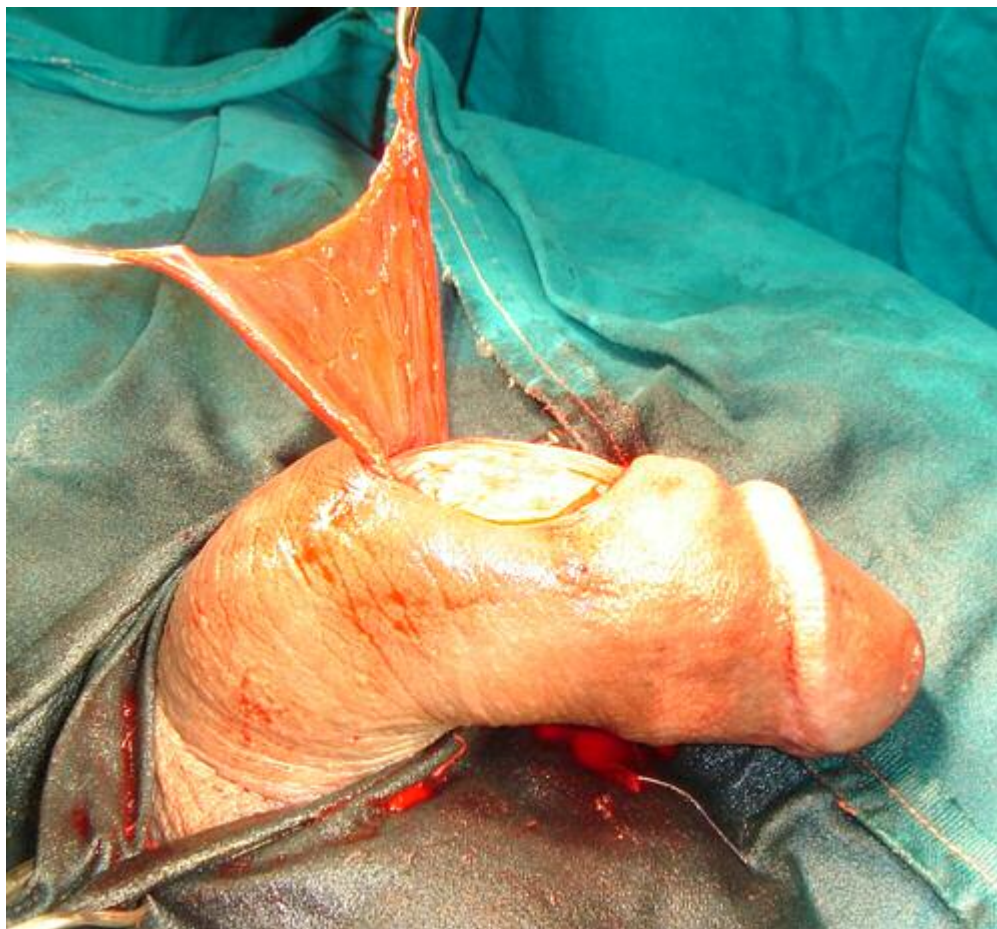
Peer Review

1
2
3
4
5
6
7
8
9
10
11
12
13
14
15
16
17
18
19
20
21
22
23
24
25
26
27
28
29
30
31
32
33
34
35
36
37
38
39
40
41
42
43
44
45
46
47
48
49
50
51
52
53
54
55
56
57
58
59
60



Dissection of the Dartos flap.
176x208mm (72 x 72 DPI)

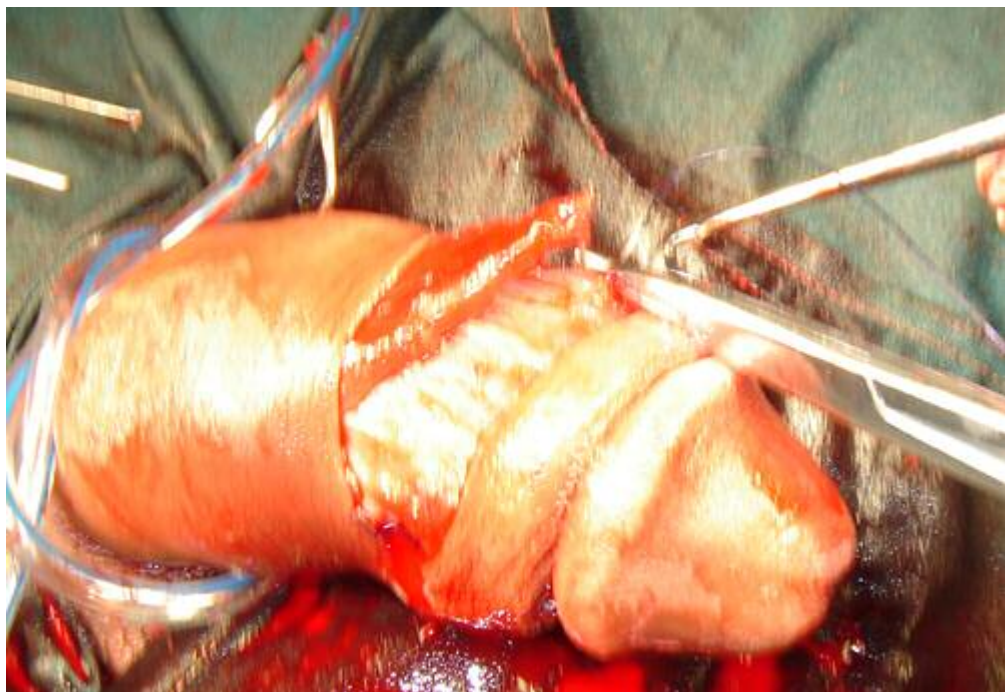1
2
3
4
5
6
7
8
9
10
11
12
13
14
15
16
17
18
19
20
21
22
23
24
25
26
27
28
29
30
31
32
33
34
35
36
37
38
39
40
41
42
43
44
45
46
47
48
49
50
51
52
53
54
55
56
57
58
59
60



Dartos flap developed.
176x162mm (72 x 72 DPI)



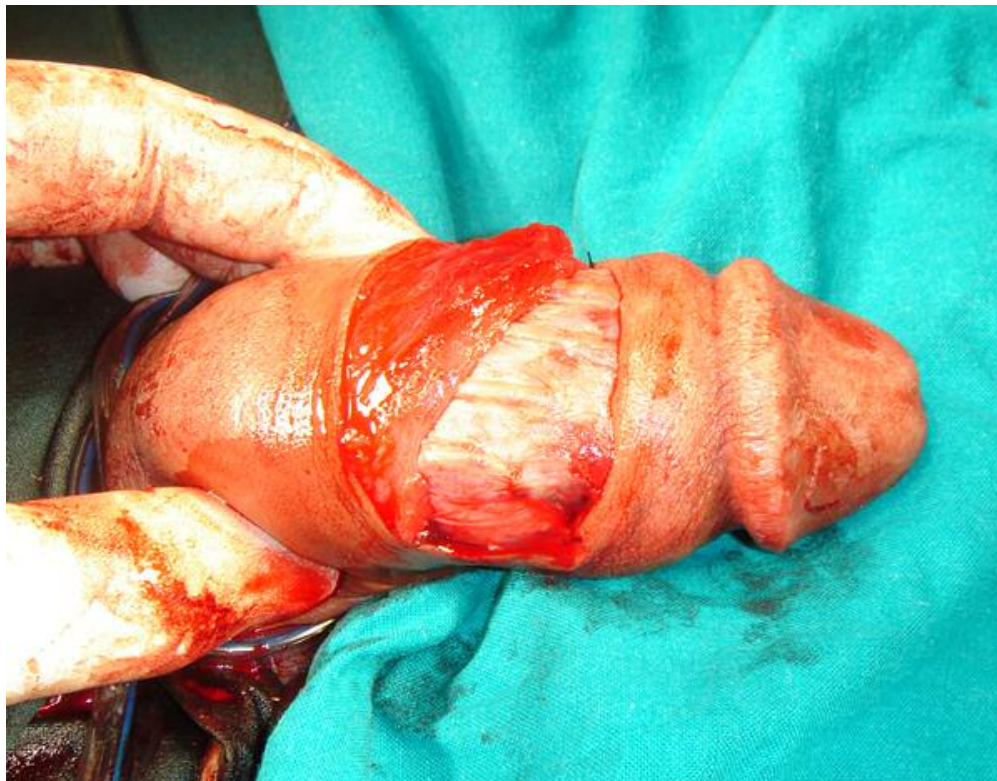
1
2
3
4
5
6
7
8
9
10
11
12
13
14
15
16
17
18
19
20
21
22
23
24
25
26
27
28
29
30
31
32
33
34
35
36
37
38
39
40
41
42
43
44
45
46
47
48
49
50
51
52
53
54
55
56
57
58
59
60



Suturing of the Dartos flap.
176x121mm (72 x 72 DPI)

Review

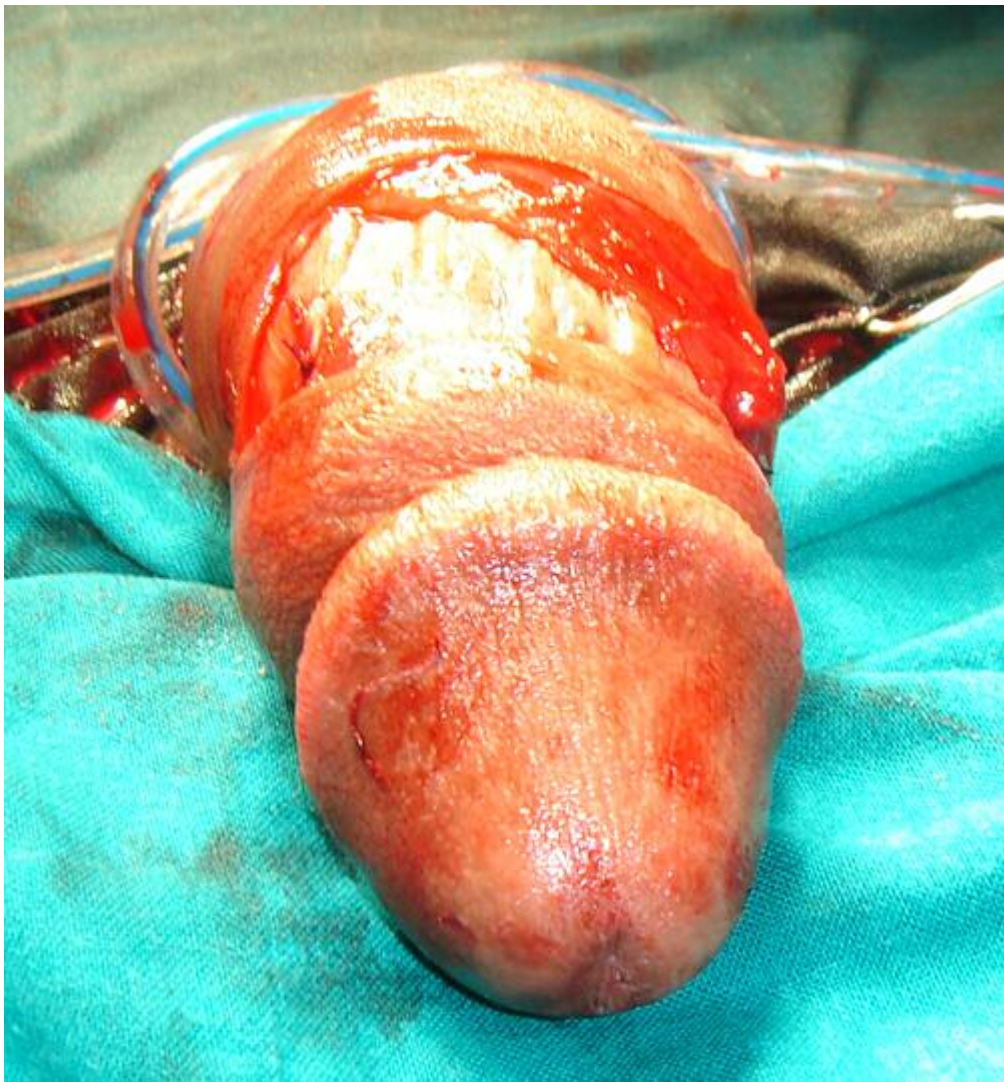1
2
3
4
5
6
7
8
9
10
11
12
13
14
15
16
17
18
19
20
21
22
23
24
25
26
27
28
29
30
31
32
33
34
35
36
37
38
39
40
41
42
43
44
45
46
47
48
49
50
51
52
53
54
55
56
57
58
59
60



Dartos flap in place.
211x164mm (72 x 72 DPI)

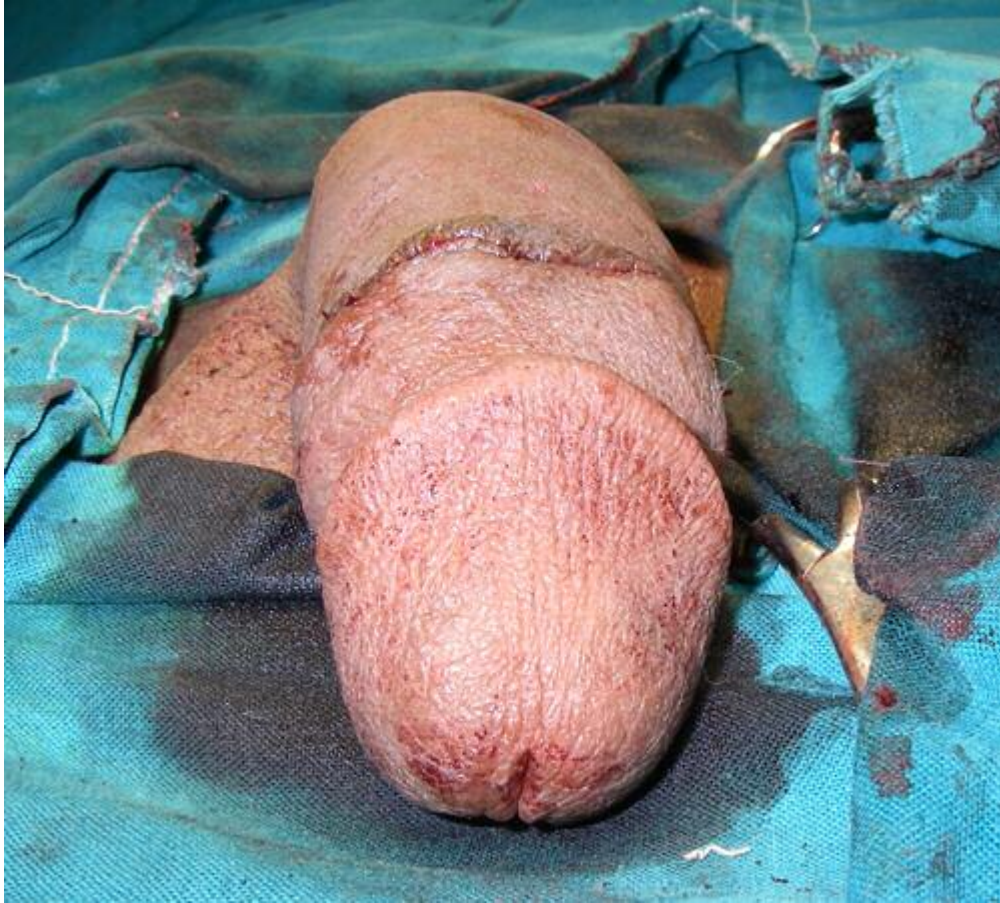
Review

1
2
3
4
5
6
7
8
9
10
11
12
13
14
15
16
17
18
19
20
21
22
23
24
25
26
27
28
29
30
31
32
33
34
35
36
37
38
39
40
41
42
43
44
45
46
47
48
49
50
51
52
53
54
55
56
57
58
59
60



Dartos flap case after correction.
176x189mm (72 x 72 DPI)

1
2
3
4
5
6
7
8
9
10
11
12
13
14
15
16
17
18
19
20
21
22
23
24
25
26
27
28
29
30
31
32
33
34
35
36
37
38
39
40
41
42
43
44
45
46
47
48
49
50
51
52
53
54
55
56
57
58
59
60



Skin realignment case after correction.
176x159mm (72 x 72 DPI)

SW